



ISSN: 2520-5234

Available online at <http://www.sjomr.org>

SCIENTIFIC JOURNAL  
OF MEDICAL RESEARCH

Vol. 3, Issue 9, pp 1-2, Winter 2019



## CASE REPORT

# Bilateral Giant Fibromas of Labia Majora in a Middle Age Woman

Neamah M. Alali <sup>1</sup>

<sup>1</sup> Consultant Surgeon, M.B.Ch.B.(Bag.),F.R.C.S.(Glas.),F.R.C.S.(Edin.), Kerbala, Iraq.

### ARTICLE INFORMATION

#### Article History:

Submitted: 7 April 2018  
Revised version received:  
29 July 2018  
Accepted: 2 August 2018  
Published online: 1 March 2019

#### Key words:

Tumors  
Samawah  
Pelvic inspection  
Bilateral Vulvar Fibromas

#### Corresponding author:

Neamah M. Alali  
Email: [dr.neamahalali@gmail.com](mailto:dr.neamahalali@gmail.com)  
Consultant Surgeon  
M.B.Ch.B.(Bag.)  
F.R.C.S.(Glas.)  
F.R.C.S.(Edin.)  
Kerbala  
Iraq

### ABSTRACT

Vulva tumors are generally rare disease entity encountered in clinical practice of gynecology, and it is especially so at a young age. Presented here is a case report of painless progressively enlarging bilateral vulvar tumors which evolved over many years. The bigger tumor of right labium majus was excised and subjected to histopathological examination which revealed it to be a fibroma.

*Copyright©2019, Neamah M. Alali This is an open access article distributed under the Creative Commons Attribution License, which permits unrestricted use, distribution and reproduction in any medium, provided the original work is properly cited.*

**Citation:** Alali N.M. "Bilateral Giant Fibromas of Labia Majora in a Middle Age Woman". Sci. J. Med. Res. 2019, 3 (9): 1-2.

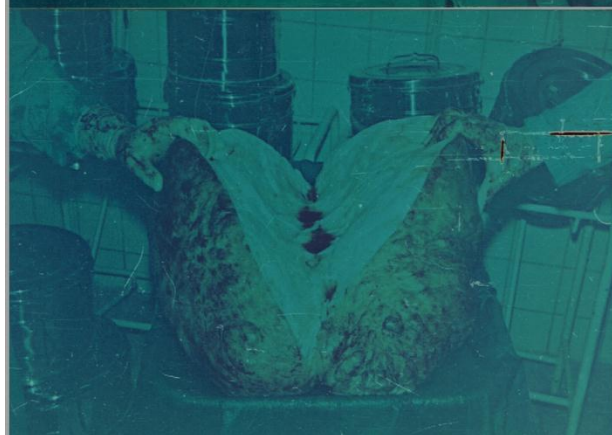
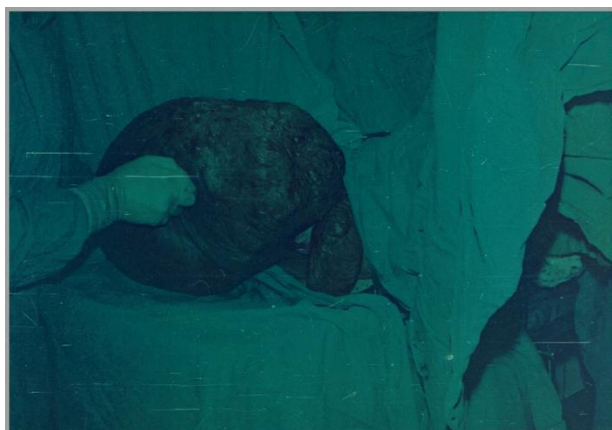## INTRODUCTION

Tumors of the vulva are rare, few published cases have been reported about this condition<sup>1</sup>. Apart from malignant tumors, fibromas fall in the group of the most common benign tumor of vulva though they as well occur very rarely<sup>2</sup>. The commonest benign tumors of the vulva include: the fibroma, papilloma, lipoma, angioma, neuromas, lymphangiomas, neurofibromas and adenomas<sup>3</sup>. Of these fibromas are the most common form of benign masses<sup>4</sup>. When located in the vulva, they occur more often in the labia majora, clitoris, vestibule, and posterior commissure<sup>5</sup>. Treatment of vulvar tumors is by excision<sup>6</sup>. This case report describes a unique huge tumor, and a smaller one from right and left labia majora respectively.

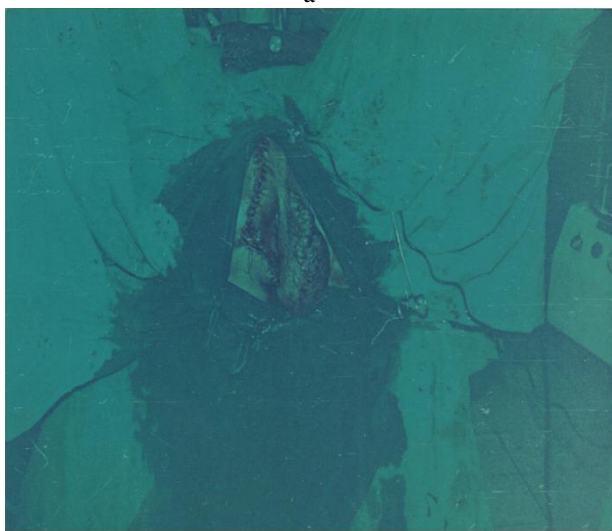
## CASE PRESENTATION

A 42 old multiparous woman was referred to me in Samawah General Hospital with huge mass originating from the right labium majus, it was a firm globular mass with thick irregular skin surface, the tumor was 65-cm in length,45-cm at greatest width, the base of attachment was about 20-cm,it was sessile. The smaller mass originating from left labium majus was about 20-cm in length and 10-cm in width. These swellings had progressively been increasing in size over many years. On general examination the patient was found to be generally healthy looking patient. Pelvic inspection and palpation revealed bilateral giant swellings, no lymph nodes were palpable in inguinal regions. Under general anesthesia the huge tumor on the right side was excised

through an incision encircling the base of attachment. Tumor weighed 13-kilograms.



-a-



-b-

Figure 1(a and b): Tumor of the vulva.

## Discussion

Tumors arising in the vulva commonly begin as small masses that do not normally attract medical attention<sup>7</sup>, but occasionally, they attain, huge sizes that can impair victim's lifestyle and may in fact affect sexual and reproductive functions<sup>8</sup>, in addition to the weight they are carrying with difficulties of walking, sleeping, turning and personal hygiene<sup>9,10</sup>. These tumors may have tremendous impact on someone's life ranging from withdrawal to marriage failure or divorce<sup>11</sup>. Vulvar fibroma may recur after incomplete removal<sup>12</sup>.

## Conclusions

This case reports bilateral vulvar fibromas, the excised right one is the biggest reported.

## REFERENCES

1. Abasiattai A.M., Umoiyoho A.J., Umanal N. and Utuk N.M. "Giant fibroma of the vulva". *BMJ Case Report*. 2010; Available from <http://www.ncbi.nlm.nih.gov/pmc/articles/PMC3028574>.
2. Rehana N., Chowdhury H.H. and Awasthi S. "A large fibroma polyp of labia majora-A case report". *Clin. Case Rep*. 2013; 3(8):1-2.
3. De Lima Filho O.A. "Fibroma of the vulva :Molluscum pendulum". *Rev Gynecol Obstet*. 1952; 46(4):287-296.
4. Haley J.C., Mirowski G.W. and Hood A.F. "Benign vulvar tumors". *Semin Cutan Med Surg*. 1998; 17(3):196-204.
5. Filho L.L.L., Lopes I.M.R.S., Filho E.S.F., Neto T.R.G. and Lopes L.R.S. "Giant soft fibroma located in the vulva: a case report". *Surg. Cosmet. Dermatol*. 2012; 4(2):200-202.
6. Haley J.C.I., Mirowski G.W., Hood A.F. "Benign vulvar tumors". *Semin Cutan Med Surg*. 1998; 17(3):196-204.
7. Ajibona O.O., Richards C.J. and Davies Q. "A distinctive vulvar fibroma of so-called prepubertal type in a postmenopausal patient". *J. Clin. Path.* 2007; 60(4):437-438. DOI:[10.1136/jcp.2006.040428](https://doi.org/10.1136/jcp.2006.040428).
8. Wilkinson E.J., Xie D. "Benign diseases of the vulva". In Kurman R.J. editor; Blaustein pathology of the female genital tract .Fifth edition. New Delhi; Springer-Verlag, 2002:37-98.
9. Onwuhafua P.I. "Fibroma of the vulva: report of a case". *Trop J Obstet Gynecol*. 2001; 18:93-94.
10. Berlin M. and Berlin S. "Fibroma of the vulva: a case report". *J Reprod Med*. 2007; 52(6):533-534.
11. Valeminsky M. Jr. "Extremely large vulvar fibroma in a 15 years old girl". *Neuro Endocrinology Letters*. 2012; 33(6):600-602.
12. Chen D.C., Chen C.H., Su H.Y., Yu C.P. and Chu T.Y. "Huge pedunculated fibroma of the vulva". *Acta Obstet Gynecol Scand*. 2004; 83(11):1091-1092. DOI:[10.1111/j.0001-6349.2004.0122b.x](https://doi.org/10.1111/j.0001-6349.2004.0122b.x).